

Digital Dermatitis

The dynamics of digital dermatitis in dairy cattle and the manageable state of disease

Dörte Döpfer, DVM, MSc, PhD, assistant professor Food Animal Medicine, School of Veterinary Medicine, UW Madison, Madison, WI 53706, USA
Phone: +1 (608) 2361186, email: dopferd@vetmed.wisc.edu

Definition of Digital dermatitis from the keynote lecture about the International Atlas of lesions of cattle feet (Greenough et al 2008):

Digital Dermatitis (DD): a circumscribed superficial ulceration of the skin along the coronary band, commonly on the plantar interdigital, ridge of the rear foot

Clinical presentation and location:

Digital dermatitis is a multifactorial, infectious, superficial dermatitis of the digital skin of cattle that may be very painful upon touch and has a characteristic fetid odor. The most common site of DD lesions is the palmar/plantar interdigital ridge of the foot – especially the rear feet, but other sites include the skin of the interdigital cleft where they can be found on Interdigital Hyperplasias, the skin around the dew claws, the heel, sometimes under-running the sole, and the dorsal aspect of the coronary band, where they may be associated with a vertical wall crack. A white epithelial margin and overlong hair have been described around acute ulcerative DD lesions while more chronic stages of DD are associated with dyskeratosis, filamentous or mass-like epithelial proliferations.

Early or intermediate DD lesions are small circumscribed epithelial defects that have been described as ‘Focal Bacterial Keratolysis’ by Read et al. (1998). Neglected cases of acute ulcerative DD may develop painful phlegmones and infections of the deep digital structures that may require surgical care for recovery.

Histopathological alterations of bovine digital skin affected by acute ulcerative DD lesions are similar in many different countries as reported by Read et al. (1998).

Etiology:

Digital dermatitis is considered a multifactorial infectious claw disease with a strong bacterial component. Best candidates for etiological bacterial agents of DD are spirochetes of the *Treponema* spp. closely related to *Treponema phagedaenis*, *T. vincentii*/*T. medium*, and *T. denticola* (Evans et al 2009, Strub et al. 2007, Choi et al 1997). The discussion concerning the etiology of DD is not conclusive and Koch’s postulates nor the modern molecular variants of those postulates have not been fulfilled to prove the etiology of DD (Read and Walker 1997). Other bacterial species isolated from acute DD lesions are *Fusobacterium* spp., *Campylobacter* spp., *Prevotella* spp. among many others.



Epidemiology and risk factors:

Young cattle kept under unhygienic conditions on farms that purchase cattle from infected premises are prone to develop acute ulcerative DD lesions that can accumulate over time to produce outbreaks associated with lameness and production losses (Rodriguez-Lainz et al. 1999, 1996). Other risk factors are low parity, early stages of lactation, the cooler months of the year when cattle are kept indoors in freestals, high producing cows, wet corrals and cattle affected by Interdigital dermatitis (ID) and Interdigital Hyperplasias (Holzhauer et al. 2006, Somers et al. 2005, Rodriguez-Lainz et al. 1999, 1996).

Controversy and History:

Digital Dermatitis lesions have first been described by Cheli and Mortellaro in 1974 but oral reports of the disease are many years older (Brizzi, personal communication 1992). Pictures of DD lesions can be found in the early publications about ID (Toussain Raven and Cornelligo 1969) which reflects the possibility that early DD has been misclassified before being recognized as a claw disease on its own.

During the eighties and early nineties of the last century, the disease caused concern due to the recurrent and explosive outbreaks with increasing clinical severity of the acute ulcerative DD lesions. These recurrent outbreaks have turned DD into the most important infectious claw disease with rising incidence worldwide, a public health concern due to the usage of antibiotic footbathing agents during control of DD and a serious animal welfare concern due to longstanding painful DD episodes associated with lameness. Herd and Claw Health managers and veterinarians have not succeeded in eliminating DD from cattle since the disease made its first appearance and consequently DD has taken its place among the important production diseases (Frankena et al 2009).

The notion of early, acute and chronic stages of DD may vary by region in the world where North America is used to see more proliferative lesions as reflected by the term 'Hairy Heel Warts' as compared to for example Western Europe where acute DD seems to be less proliferative or detected earlier. Another controversial discussion has developed around the question whether DD and ID are part of the same digital disease syndrome called 'Dermatitis' and should be treated as one entity. This discussion is justified by the fact that chronic DD and ID have an overlap in clinical manifestation of dyskeratotic digital skin and by the fact the DD has no clear etiology.

Classification and scoring system for different stages of DD:

The idea of classifying the different stages stems from longitudinal follow-ups on lesions where initially unaltered bovine digital skin develops early lesions, followed by acute ulcerative lesions and progresses into chronic stages that may present with dyskeratotic or proliferative aspects of abnormal digital epithelium.

The M-stages represent stages during the course of DD (Greenough et al 2008, Döpfer et al 2004, Döpfer et al. 1997). Here, the 'M' stands for 'Mortellaro'.

The five M-stages are defined as:

M0 normal digital skin without signs of DD, some authors have encountered difficulties finding an example for intact bovine digital skin without signs of any claw diseases, but young animals, such as calves and pre-partum heifers are candidates for being negative for claw diseases.

M1, early, small circumscribed red to gray epithelial defect of less than 2 cm in diameter that precedes the acute stages of DD (M2). In addition, M1 stages can appear between acute episodes of DD lesions or within the margins of a chronic M4 lesion as an intermediate stage.

M2, acute, active ulcerative (bright red) or granulomatous (red-gray) digital skin alteration, >2 cm in diameter, commonly found along the coronary band in addition to around the dew claws, in wall cracks and occasionally as a sole defect.

M3, healing stage within 1 to 2 days after topical therapy, where the acute DD lesion has covered itself with a firm scab-like material

M4, late chronic lesions that may be dyskeratotic (mostly thickened epithelium) or proliferative or both. The proliferations may be filamentous, scab-like or mass proliferations

M4.1, the additional stage refers to the chronically affected foot that displays the M4 stage in addition to the M1 stage.

Animals may be typed into three courses of disease. This system has been used before for clinical trials, herd monitoring, and for models of transmission of DD (Holzhauer et al 2008, Döpfer et al 2004):

Type 1: an animal that does not develop acute M2 lesions of DD, but can show M1 or M4 stages of DD.

Type 2: an animal that develops one acute M2 lesion followed by a long period characterized by absence of acute DD (the length of the period of absence of acute M2 lesions depends on the period of observation for a given study design, but can vary from several months to years).

Type 3: an animal that develops repeated episodes of acute M2 lesions within a defined period of time (the time interval between repeated episodes of M2 lesions can be as short as 10 to 14 days)

Figure 1 illustrates the different M-stages during the course of DD.

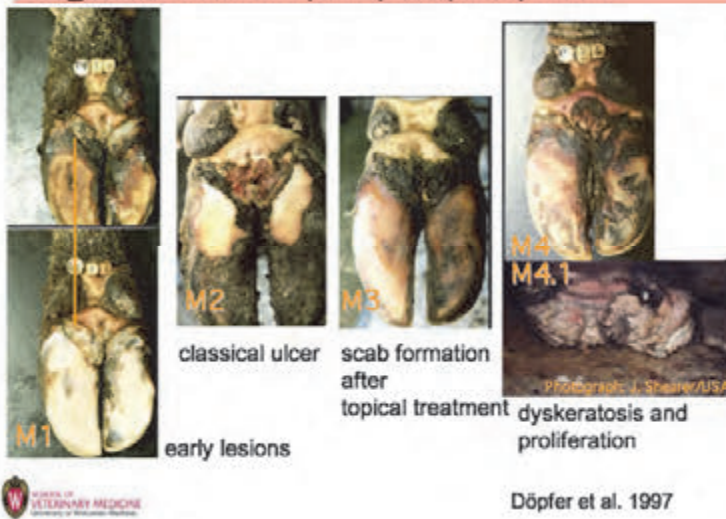


Conclusion

Digital dermatitis has not been eliminated from cattle herds since its emergence and the disease is here to stay with increasing numbers of chronic lesions in endemically affected herds. It is of great importance to define the best-practice prevention and control program to reach the endemically infected state for DD that is acceptable to producers and claw health managers. This acceptable level of infection would tolerate sporadic individual cases of lameness and acute DD lesions (M2) that are readily detected and efficiently treated. Major outbreaks of acute lesions would be prevented using best-practice hoofbaths in addition to standard records about lameness, trimming, and treatments. In the long-term all cattle would be typed according to their type of course of DD. The strategies to define the 'manageable state of disease' will be discussed.

Figure 1: the different stages of DD during the course of disease

Stages of DD: M1, M2, M3, M4, M4.1



References:

Cheli, R. and C.M. Mortellaro 1974. La dermatitis digitale del bovino. Proc. 8th International Conference on Diseases of Cattle, Milan Italy, Proc. 208-213.

Choi, B.K., H. Nattermann, S. Grund, W. Haider, and U.B. Göbel 1997. Spirochetes from digital dermatitis lesions in cattle are closely related to treponemes associated with human periodontitis. *Int. J. Syst. Bacteriol.* 47:175-81

Greenough, R., Mülling, C., Döpfer, D., and D. Tomlinson (2008). International atlas of lesions of cattle feet. Proc. XVth International Symposium for Lameness in cattle and Disorders of the ruminant digit in Kuopio, Finland, 9th to 12th of June, 2008, Keynote lecture

Döpfer, D., R.M. van Boven, and M.C.M. de Jong (2004). A mathematical model for the dynamics of digital dermatitis in dairy cattle. 13th ICPD July 19th to 22nd 2004, Lansing/MI/USA. Proc. p 36

Döpfer D., A. Koopmans, F.A. Meijer, I. Szakall, Y.H. Schukken, W. Klee, R.B. Bosma, J.L. Cornelisse, A.J.A.M. van Asten, and A.A. ter Huurne 1997. Histological and bacteriological evaluation of digital dermatitis in cattle, with special reference to spirochaetes and *Campylobacter faecalis*. *Vet Rec.* 140(24):620-3.

Evans, N. J., Brown, J. M., Demirkan, I., Murray, R. D., Vink, W. D., Blowey, R. W., Hart, C. A., Carter, S. D. 2009. Three unique groups of spirochetes isolated from digital dermatitis lesions in UK cattle. *Vet Microbiol* 130:141-50

Frankena, K., Somers, J. G., Schouten, W. G., van Stek, J. V., Metz, J. H., Stassen, E. N., Graat, E. A., 2009. The effect of digital lesions and floor type on locomotion score in Dutch dairy cows. *Prev Vet Med* 88:150-7

Holzhauser, M., Bartels, C. J., Dopfer, D., van Schaik, G. 2008. Clinical course of digital dermatitis lesions in an endemically infected herd without preventive herd strategies. *Vet J* 177:222-30.

Holzhauser, M., Hardenberg, C., Bartels, C.J. and Frankena, K. 2006. Herd- and cow-level prevalence of digital dermatitis in the Netherlands and associated risk factors. *J. Dairy Sci.* 89(2):580-8

Read, D.H., and R.L. Walker 1998. Papillomatous digital dermatitis (footwarts) in California dairy cattle: clinical and gross pathologic findings. *J. Diag. Invest.* 10:67-76.

Rebhun, W.C., M. Payne, J.M. King, M. Wolfe, and S.N. Berg (1980). Interdigital Papillomatosis in dairy cattle. *JAVMA* 177:437-44

Rodriguez-Lainz, A., P. Mellendez-Retamal, D.W. Hird, D.H. Read and R.L. Walker 1999. Farm- and host-level risk factors for papillomatous digital dermatitis in Chilean dairy cattle. *Prev. Vet. Med.* 42:87-97.

Rodriguez-Lainz, A., D.W. Hird, R.L. Walker and D.H. Read 1996. Papillomatous digital dermatitis in 458 dairies. *JAVMA* 209:1464-67.

Somers, J.G., Frankena, K. and E.N. Nordhuizen-Stassen 2005. Risk factors for digital dermatitis in dairy cows kept in cubicle houses in The Netherlands. *Prev. Vet. Med.* 71(1-2):11-21.

Strub, S., J.R. van der Ploeg, K. Nuss, C. Wyss, A. Luginbühl and A. Steiner 2007. Quantitation of *Gugenheimella bovis* and treponemes in bovine tissues related to digital dermatitis. *FEMS Microbiol. Lett.* 269(1):48-53

Toussain Raven, E. 1969. Footrot in cattle [Een specifieke, besmettelijke ontsteking van de tussenklauwenhuid bij het rund]. *Tijdschr. Diergeneesk.* 94:190-207 in Dutch

Walker, R.L., D.H. Read, K.J. Loreta and R.W. Nordhausen 1995. Spirochetes isolated from dairy cattle with papillomatous digital dermatitis and interdigital dermatitis. *Vet. Microbiol.* 47:343-55

